

Bowel Endometriosis Management by Colorectal Resection: Laparoscopic Surgical Technique & Outcome

Dipak Limbachiya, MD, Rajnish Tiwari, MD, Rashmi Kumari, MS, Manoj Agrawal, MS

ABSTRACT

Background and Objectives: Bowel deep infiltrating endometriosis (DIE) management by colorectal resection is a complex procedure. The purpose of the present study is to delineate a meticulous approach to the assessment of the patient, step-wise surgical technique, pre, and postoperative care, and its short-term and long-term outcomes.

Methods: This is a single-center retrospective study done on patients of bowel DIE managed by colorectal resection between January 1, 2019 to June 30, 2021.

Results: There was a significant improvement in the symptomatology of patients post-surgery. Our surgical technique is feasible with acceptable short-term and long-term outcomes.

Conclusion: Bowel DIE management can be proficiently executed with a proper diagnostic approach, appropriate surgical expertise with exhaustive pelvic anatomy knowledge especially concerning autonomic nerve plexus.

Key Words: Assessment of patients, Bowel deep infiltrating endometriosis, Colorectal resection, Surgical technique.

INTRODUCTION

Endometriosis is usually classified as three subtypes, peritoneal (15% – 50%), ovarian (2% – 10%) and deep infiltrating

endometriosis (DIE) (20%).¹ DIE is the most grievous of all owing to its nodule-forming tendency which has infiltrating attributes to its surrounding structures. It customarily does not respond to medical management due to its fibrotic nature with compromised vascularity. DIE is more frequently identified as localized to the posterior compartment of the pelvis where it can involve the uterosacral ligaments, torus uterini, ureters, bowel segment, and vaginal wall. DIE involving bowel constitutes 5% to 12% of patients.² The rectosigmoid and rectum are involved in 70% to 90% of cases of bowel DIE followed by the ileum, appendix, and cecum.³

Diagnosis of bowel DIE is principally accomplished by thorough clinical history, elaborate clinical examination, and additionally assisted by imaging modalities. Surgical excision is recommended for the treatment of bowel DIE when the lesion becomes symptomatic and has not responded to medical management.⁴ A multidisciplinary treatment approach along with laparoscopic surgical management has been accepted as the preferred treatment for bowel endometriosis. The category of surgical treatment approach for bowel DIE is conventionally determined after an assessment of the lesion size, number, location, depth of infiltration, and extent of bowel lumen stenosis.^{5,6} Surgical management of bowel DIE by conservative surgery (nodulectomy) can be done by shaving, mucosal skinning, and disc excision technique. Shaving and discoid bowel excision techniques are usually indicated in cases of unifocal, superficial/deep (respectively), and smaller than 3 cm lesions. These bowel operative techniques have the advantages of simplified surgical technicality with decreased operating duration, fewer complication rates, shorter hospitalization stays, and better functional outcomes in terms of continence and constipation in comparison to segmental resection. Studies have shown that the shaving technique has better pregnancy rates compared to the discoid and segmental resection techniques. These techniques are also preferred for lesions involving low rectum compared to segmental resection, to avoid extensive dissection and minimize significant postoperative morbidity like bowel diversion stoma. The main disadvantage of these conservative techniques, according to available literature, is an increased recurrence rate in comparison with segmental resection.⁷

Department of Gynaecological Endoscopy, Eva Women's Hospital, Ahmedabad, India. (all authors)

Disclosure: none

Conflict of interests: none

Funding sources: none

Informed consent: Dr. Dipak Limbachiya declares that written informed consent was obtained from the patient/s for publication of this study/report and any accompanying images.

Address correspondence to: Dr. Dipak Limbachiya, MD, Department of Gynaecological Endoscopy, Eva Women's Hospital, Neelkanth Park 2, Ghoda Camp Road, Shahibag, Ahmedabad, Gujarat, India, Telephone: +91-9825028771, E-mail: limbachiyaadipak63@gmail.com.

DOI: 10.4293/JSLS.2022.00075

© 2023 by SLS, Society of Laparoscopic & Robotic Surgeons. Published by the Society of Laparoscopic & Robotic Surgeons.

According to the available literature, various recommended criteria for bowel DIE management by colorectal resection technique are: patients with multifocal or multicentric intestinal lesions, large nodules (> 3 cm in diameter), presence of greater than 40% bowel luminal stenosis, more than one-third circumference of bowel wall involvement, nodule located in sigmoid colon or at higher site or presence of symptoms even after conservative surgery (nodulectomy).^{5,6,8} Resection and anastomosis of bowel segment for DIE is considerably a complex surgery, which requires a multidisciplinary surgical expertise team. The literature recognizes numerous studies related to bowel DIE managed by resection and anastomosis but no standardized surgical technique is available for the same.^{4,9} There is also ongoing debate regarding the preference of shaving or discoid excision technique over colorectal bowel resection and anastomosis as resection of bowel segment is associated with more complications as per available literature. We present our study conducted at a single center on bowel DIE lesion management by laparoscopic resection and anastomosis along with a step-wise description of the surgical technique.

MATERIAL AND STUDY DESIGN

This was a single-center retrospective observational study. Twenty-two patients bowel DIE managed by laparoscopic bowel resection and anastomosis between January 1, 2019 to June 30, 2021 were enrolled in the study. Patients with a) bowel DIE management by laparoscopic conservative surgery such as disc excision ($n = 15$) or shaving ($n = 139$) technique, or b) patients with bowel DIE are managed by laparoscopic resection and anastomosis with a follow-up of less than 12 months were excluded from the study.

Written informed consent was taken from all the patients. Data were collected from patients' case sheets, surgical videos, and follow-up records. All patient baseline characteristics, clinicopathological details, and per operative surgical details were documented. Any complications related to surgery, perioperative, immediate, and short-term were recorded. All patients were called for follow-up at one month, three months, and thereafter every six months through an outpatient visit or telephonic call. Every follow-up visit had a relevant symptomatic questionnaire, clinical examination, and imaging as and when required (preferably by ultrasound of the pelvis or transvaginal ultrasound). Visual analog scale (VAS) and numerical rating scale (NRS) were utilized for pre- and postoperative improvement in symptoms-related pain assessment.

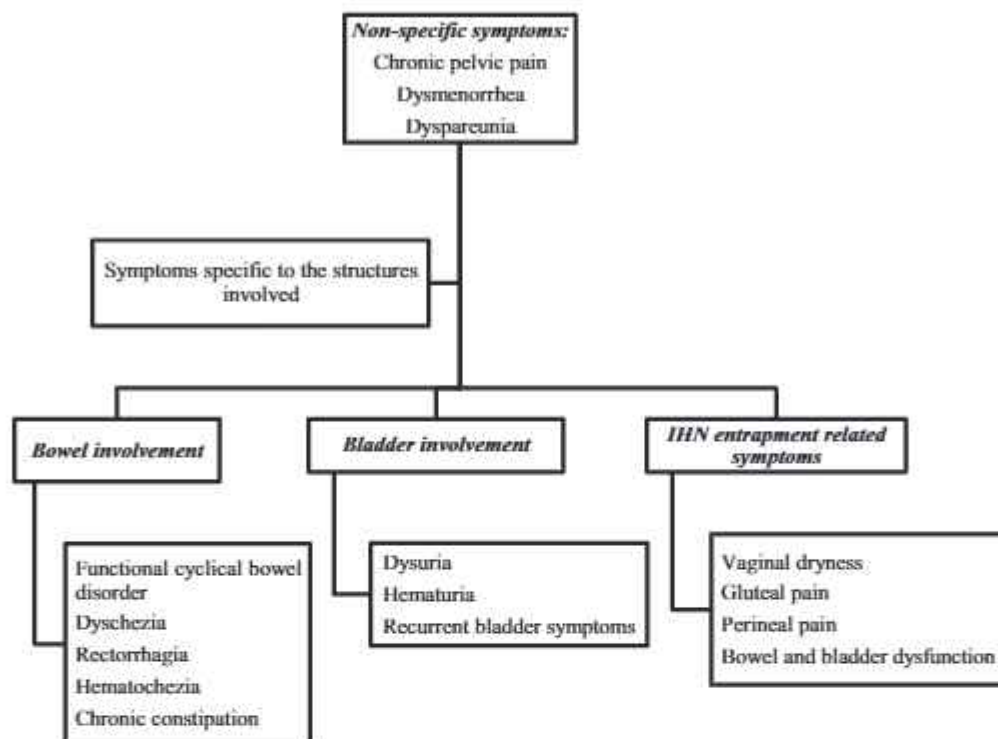
Wilcoxon signed rank test was the statistical method used for data analysis.

Assessment of Patient

There are no conclusive guidelines regarding the method of evaluation for patients suspected of bowel DIE. A detailed patient clinical history along with an elaborative physical examination by an experienced clinician is itself elucidative while dealing with DIE cases. Bowel DIE usually produces cyclical lower abdominal pain in addition to generalized symptoms such as dysmenorrhea and dyspareunia. Specific bowel-related symptoms such as dyschezia, constipation, rectal bleeding, and catamenial diarrhea are being enumerated by varied patients.¹⁰ Symptomatology depends on the specific pelvis site involvement¹¹ (**Flowchart 1**). Pre-operative scoring for pain symptoms was performed using a 10-point VAS score (0 = no pain; 10 = severe pain). The patient was evaluated for any significant past surgical history (caesarean section, dilatation & curettage, or previous surgical intervention done for any type of endometriosis) which could be an inciting risk factor or which could give a preliminary idea about the disease's extent.

Clinical examination consisting of a per abdomen and a detailed pelvic bimanual examination is an effective diagnostic tool in detecting deep infiltrating endometriosis lesions and their extent (**Flowchart 2**).

Varied imaging modalities provide substantial information regarding the presence, location, and extent of DIE while also assisting in optimizing preoperative planning. The preferred imaging techniques to localize and specify endometriotic lesions are transvaginal sonography (TVS) and magnetic resonance (MR) imaging (**Flowchart 3**). TVS is well recognized and widely established imaging modality and should be used as a first-line screening technique. MR imaging is preferably considered as a second-line imaging technique in the evaluation of DIE, especially regarding the extent of disease and depth of infiltration.¹² In our study, all patients underwent a detailed MR colonography explicitly to detect details concerning bowel endometriotic nodule number, extent, depth, and any significant bowel lumen stenosis. This step helps in pre-operative counseling with informed decisions regarding the choice of surgical technique (conservative vs segmental resection) and possible subsequent surgical complications.¹³ Different imaging modalities such as rectal sonography, barium enema, or computed tomography urography may be recommended to assess bowel/ureteric stenosis. An invasive procedure such as colonoscopy or cystoscopy



Flowchart 1. Nonspecific and site-specific symptoms of deep infiltrating endometriosis lesions involving bowel, bladder, and inferior hypogastric nerve.


is performed if a patient presents with symptoms of hematochezia or hematuria.

SURGICAL PROCEDURE

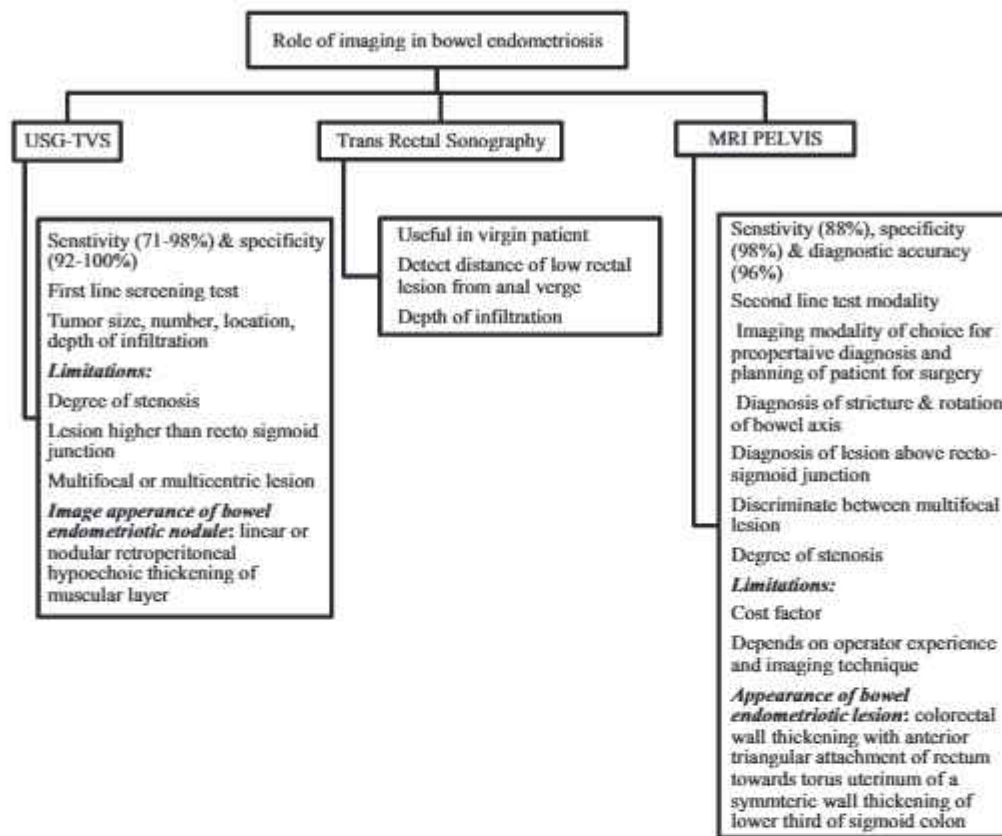
Pre-operative Preparation

Pre-operative work-up for the patient includes a thorough history taking, a detailed physical examination, and a complete

blood chemistry determination. As mentioned, all patients had baseline ultrasonography of the abdomen and pelvis with MR image of the pelvis and detailed MR colonography. Pre-operatively, the patient is given mechanical bowel preparation by using a monobasic sodium phosphate solution and two doses of injectable antibiotics, and supportive intravenous hydration, a day before surgery. Written informed consent was taken from the patient after explaining the detailed surgical procedure and its probable complications.



Flowchart 2. Clinical examination protocol in deep infiltrating endometriosis of pelvis.



Flowchart 3. The role of imaging modalities in diagnosis of deep infiltrating endometriosis.

Criteria followed for DIE bowel resection and anastomosis in our study:

- Multifocal or multicentric intestinal lesions or
- Large nodules (> 3cm in diameter) or
- Presence of greater than 40% bowel luminal stenosis or
- More than one-third circumference of bowel wall involvement.

Surgical Technique

Under general anesthesia, the patient is positioned in a modified Lloyd Davis position at 30-degree angle. Sequential compression devices are applied to lower limbs all through the surgery. Foley's catheter is inserted into the urinary bladder. The orogastric tube is used in all patients intraoperatively. The patient's right arm was abducted and the left arm was tucked with the chest and the patient tilted toward the left side. The operating surgeon stood on the left side of the patient. The first assistant holding the camera was positioned towards the head end of the table

and the second assistant on the right side helped with manipulation, grasping, and retracting tissues. The third assistant helps with vaginal manipulation. Five trocars were used in the authors' technique. The primary trocar (10mm) for the camera was inserted at 1 cm above the umbilicus. Four accessory trocars (5 mm) were inserted under direct vision, two on the left and two on the right side. The abdomen was insufflated with carbon dioxide gas and maintained at a pressure of 12 mm/Hg during the surgery. All cases were operated in a 3D laparoscopy set up by the same surgeon's team.

Steps of the procedure:

1. Adhesiolysis with inspection and evaluation of the extent of endometriosis with the restoration of normal anatomy. A detailed exploration of the peritoneal cavity and analysis are done following adhesiolysis (bowel or peritoneal adhesions), for any signs/features suggestive of endometriosis, especially over the pelvic peritoneum, sigmoid colon, rectum, uterosacral ligament, bilateral ovaries, vault, and peritoneal cavity.

2. Development of bilateral Para-vesical and lateral Para-rectal spaces (Latzko space)¹⁴

The development of these avascular spaces in the pelvis is precursory for any complex pelvic surgeries. This step further helps in the lateralization of ureters, proper identification of inferior hypogastric nerve (IHN), and thus facilitating nerve-sparing surgery.

3. Ureterolysis and Ureter tunnel dissection¹⁵

The ureter is identified in the medial fold of the broad ligament and separated from its medial peritoneal attachment. This dissection is continued in a craniocaudal direction till the uterosacral ligament. This step is replicated on the opposite side. In the case of a parametrial nodule, same-side ureteric tunnel dissection is performed till ureteric entry into the bladder wall with nerve sparing of respective side supplying branches of IHN. In cases of vault endometriosis, bilateral ureteric tunnel dissection is done as a part of surgical steps for complete vault lesion excision with a disease-free margin.

4. Nerve dissection

Nerve-sparing surgery is advocated and thus, has been performed in all the cases in the study. Medial pararectal space (Okabayashi space) dissection is performed to identify IHN, which is further separated from their medial peritoneal attachment and preserved till the hypogastric plexus at uterosacral ligament. If any entrapment of the nerve is recognized, adhesiolysis and nerve release with excision of the nodule are performed¹¹ (Figure 1).

5. Rectovaginal space dissection

The lateral wall of the mesorectum is exposed bilaterally and then central dissection proceeds with cold scissors and rectovaginal space is

dissected. Rectovaginal nodule dissection is implemented by reverse technique (Figure 2).

6. Dissection of DIE bowel segment with recognition of pertinent nerves

The rectum is adequately mobilized from both sides and posteriorly retrorectal space dissection is done. Rectal blunt dissection as well as inadvertent use of energy-based devices over the rectum are preferably avoided. Autonomic nerve injuries are most likely to occur at these key zones during resection of the rectum and therefore special care is to be implemented at these places during dissection.¹⁶

- Superior hypogastric plexus during dissection of Inferior Mesenteric Artery
- Hypogastric nerves during posterior mobilization of the rectum
- Pelvic plexus during lateral rectal mobilization

7. Application of linear stapler at the distal end of DIE bowel segment

Endo-stapler system with a green cartridge (60 mm in length) was introduced through the right lower quadrant 5-mm trocar after it was changed to a 12-mm trocar (Figure 3). Proper transverse placement of the Endo-stapler over the rectum was achieved by a 90-degree rotation along its long axis. Endo-stapler is usually placed 2 – 3 cm distal to the farthest nodular margin. The surgical Endo-stapler is fired beyond the distal end of the bowel DIE, placing the rectum under traction (Figure 4). Once the rectum is divided, the stapler is released.

8. Division of proximal end of DIE bowel segment

Proximally also 2 – 3 cm grossly diseased free margin from the DIE nodule is taken and a proximal line of cleavage of the rectum is decided. Bowel grasper is

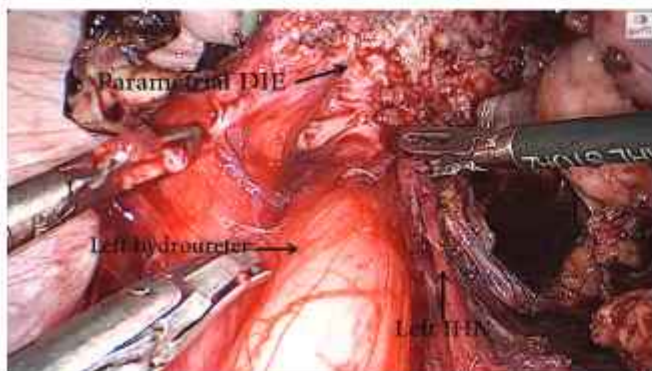


Figure 1. Entrapped left inferior hypogastric nerve by parametrial deep infiltrating endometriosis nodule consequently causing left hydroureter.

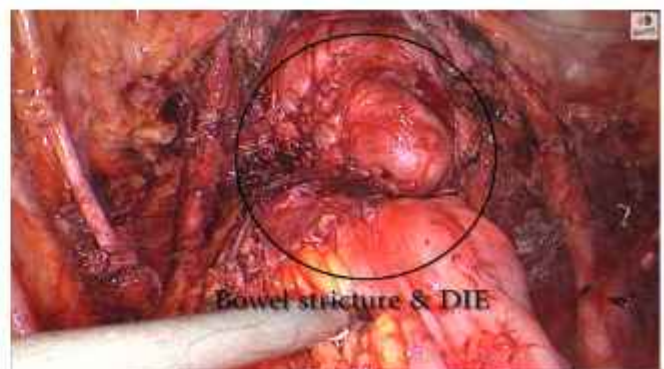


Figure 2. Stricture at rectosigmoid colon due to bowel deep infiltrating endometriosis.

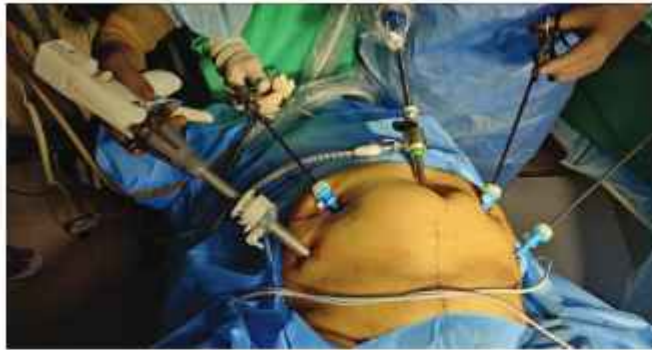

Figure 3. Port placements for linear stapler application for bowel deep infiltrating endometriosis.

applied proximal to the decided line of cleavage of the rectum to prevent the spill of Intra luminal content into the peritoneal cavity. The further proximal end of the DIE bowel segment is cut with a cold scissor.

9. Retrieval of DIE bowel segment specimen
Bowel specimen is retrieved in an endo-bag through posterior colpotomy incision in fertility-conserving surgeries and vagina in other cases.
10. Insertion of anvil and anastomosis of the rectum

Anvil is inserted in the endo-bag through posterior colpotomy incision in fertility-conserving surgeries and vagina in other cases. Subsequently, posterior colpotomy incision is closed in fertility-conserving surgeries and the vault is sutured in other cases before proceeding for rectal anastomosis.

Further anvil is fixed to the proximal cut end of the bowel through purse string stitch with 2-0 nonabsorbable polypropylene monofilament suture. First, a purse-string suture was placed circumferentially around the cut end of the proximal bowel with polypropylene monofilament suture 2-0, further fixing anvil into it and tightening the suture (**Figure 5**).

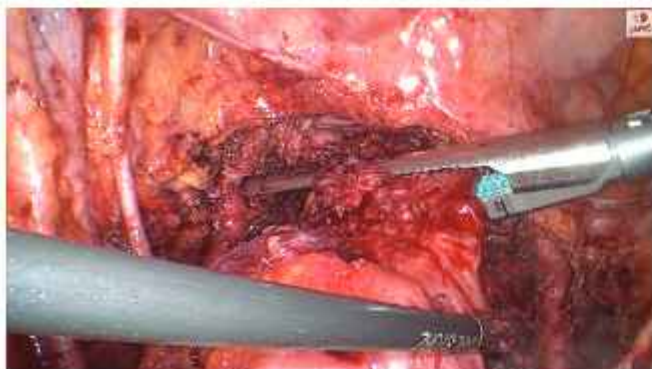


Figure 4. Application of single linear stapler (60 millimeters) beyond the distal end of bowel deep infiltrating endometriosis.

A circular stapler (29 mm) is introduced rectally through the closed distal end of the rectum and interlocked with the anvil fixed to the proximal cut end of the rectum (**Figure 6**). Proper bowel axis alignment along the anastomosis is ensured, after which a circular stapler is fired and then released with the rotatory railroad technique, taking care not to disrupt the anastomotic site. Examination of the completeness of donut tissue from the site of anastomosis ascertains the absoluteness of anastomosis (**Figure 7**). Rectal anastomosis is concluded after the placement of intermittent reinforcing stitches over the stapler line to minimize the tissue strain over the anastomosis (**Figure 8**). Further air leak test is performed under endoscopy view using a rigid proctoscope, with the bowel clamped proximal to the anastomosis. An abdominal drainage kit (ADK) drain is placed in the pelvis, for any postoperative abdominal drainage.

Postoperative Regime

The patient is kept nil by mouth for 24 hours following which a liquid diet is introduced gradually. Early mobilization is encouraged to prevent the possible complications of deep vein thrombosis and additionally, subcutaneous injectable low molecular weight heparin is given. Strict vitals and serum electrolyte monitoring is performed on daily basis and supplemented accordingly if any abnormality is detected. A further low-fiber diet is commenced from postoperative day 2 if liquids are tolerated well. Subsequently, a semisolid diet on postoperative day 3 and a full oral diet on postoperative day 4 is initiated. ADK drain is removed once the patient has passed stool. Most of the patients are usually discharged on postoperative days 4 or 5.

Follow-up Protocol

All patients were called for follow-up at one month, three months, and thereafter every six months following surgery through an outpatient visit or telephonic call. Every follow-up visit had a detailed clinical evaluation of the patients along with imaging (ultrasound or MR imaging), as and when indicated. Follow-up scoring for pain symptoms was performed using a VAS score. Patients were specifically asked about the improvement of preoperative symptoms, development of any new symptomatology related to bowel, bladder, or IHN entrapment, and improvement in VAS score post-surgery. Recurrence of any symptoms related to DIE along with long-term functional outcomes was noted. Fertility outcomes were evaluated in patients with a minimum of 12 months follow-up.

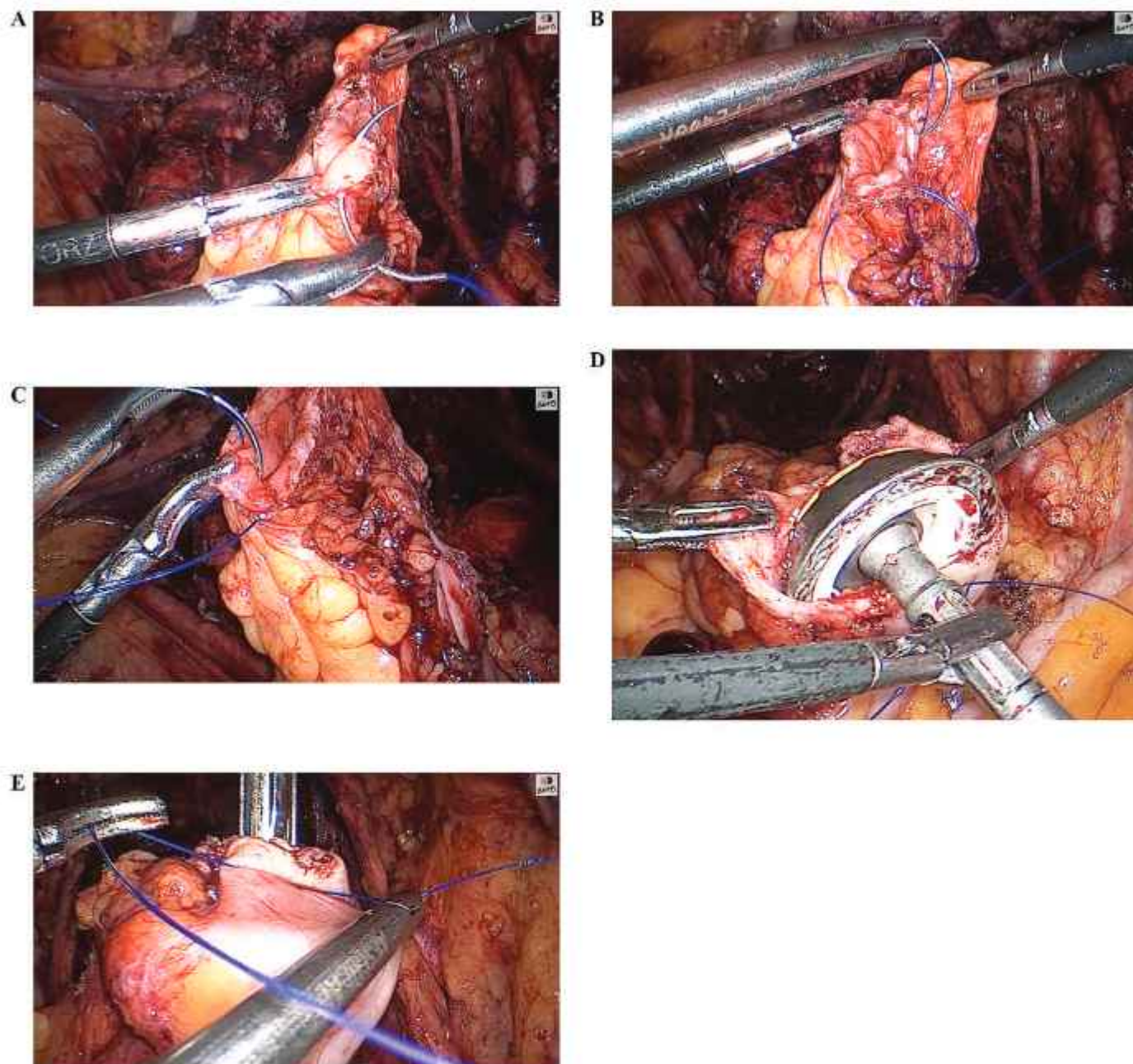


Figure 5. Laparoscopic purse string suture taken in the proximal cut end of the bowel followed by anvil placement and tightening.

RESULTS

The most common symptoms observed in our study are dysmenorrhea, chronic pelvic pain, dyspareunia, and menorrhagia. Dyschezia, a specific symptom of bowel DIE was found in all ($n = 22/22$, 100%) patients (**Table 1**). Chronic constipation was not specifically found in all

patients of bowel DIE ($n = 7/22$, 31%). Hematochezia was an associated symptom in only two cases (9%), where a pre-operative colonoscopy was performed and it was normal. Two patients had an atypical presentation, and one ($n = 1/22$, 4.5%) presented with symptoms of cyclical vomiting, fever, and rectorrhagia. Another patient ($n = 1/22$, 4.5%) with atypical symptoms had catamenial diarrhea,

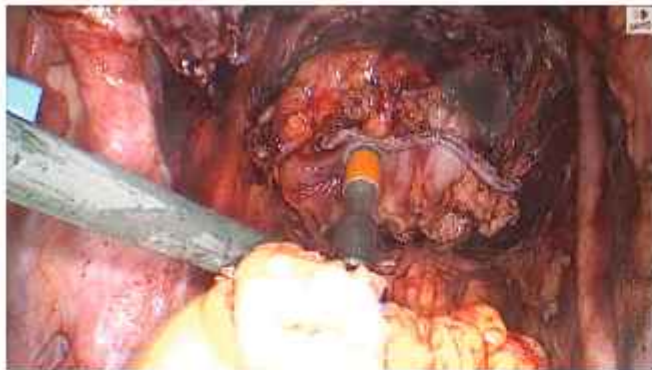

Figure 6. Laparoscopic circular stapler introduction per rectally and interlocked with the anvil fixed to the proximal cut end of the rectum.

which was later diagnosed to be a case of bowel DIE with associated inflammatory bowel disease (IBD) (ulcerative colitis).

Bladder symptomatology was elucidated only in a few cases as, dysuria ($n=3/22$, 13.5%), and cyclical acute retention of urine ($n=1/22$, 4.5%). But none of these cases had intraoperative disease in the anterior compartment, except IHN was found to be entrapped with a uterosacral nodule. Excision of the nodule and release of IHN led to symptomatic relief in the postoperative follow-up period without any further urinary dysfunction.

Patients having characteristic symptoms of vaginal dryness ($n=10/22$, 45%), perineal pain ($n=14/22$, 63.5%), and gluteal pain ($n=14/22$, 63.5%) had intraoperative findings of entrapped IHN by uterosacral nodule. Release of entrapped nerves along with excision of nodule led to

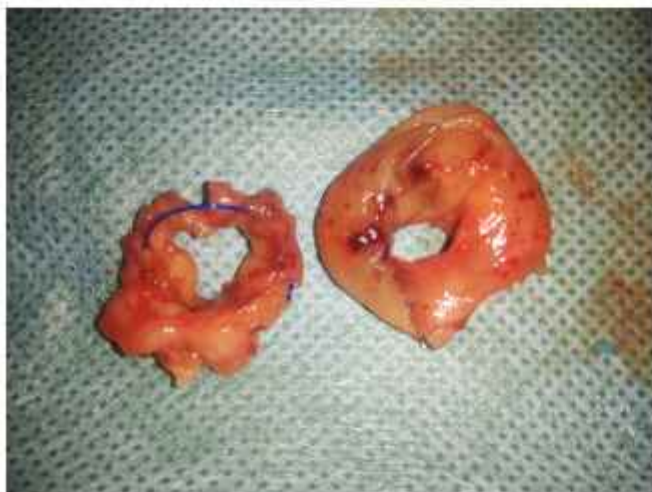

Figure 7. Completeness of donut tissue.

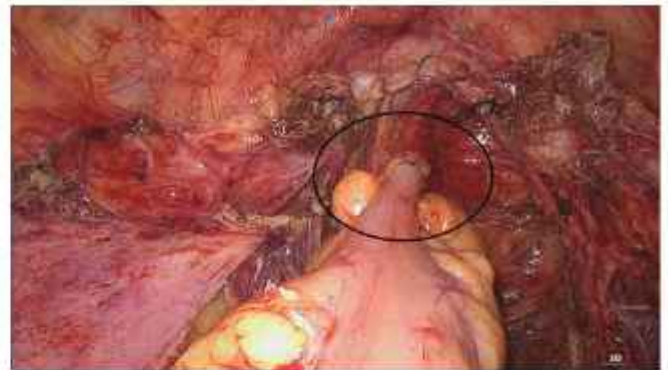


Figure 8. Endoscopic view showing end picture of colorectal anastomosis.

improvement of symptomatology in the postoperative follow-up period in all cases.

Detailed intraoperative findings along with other surgical interventions performed in the study are shown in tabular form (**Table 2**).

The most common site of bowel DIE observed in our study was the rectosigmoid junction (15/22) (between distal eight cm of the sigmoid colon and proximal five cm of the rectum). Four (4/22) patients had lesions higher in the sigmoid colon and three (3/22) had a lesion in the midrectum. None of the patients had a lesion in the low rectum (within 8 cm from the anal verge) and therefore, ultralow resection was not done in any patient (**Table 3**). Diversion stoma was not required in any of the patients in primary surgery. The maximum depth of infiltration in the study was found till the submucosal layer (**Figure 9**). None of the patients had mucosal infiltration. Nonvisualized palpable bowel endometriosis satellite lesions were perceived in four (18%) cases in resected bowel specimens. Anastomotic site donut was positive for a such lesion in two (9%) of the cases.

The Foley catheter in situ was for one day in all patients. All patients resumed their normal bladder voiding function after the removal of the Foleys catheter. None of the patients required recatheterization or prolonged catheterization. The intraperitoneal ADK drain was kept in situ for an average median duration of three days (3 – 5 days), till the time of expected resumption of normal bowel activity with spontaneous passage of stool.

Intraoperative complications were not observed in any of the cases nor were conversion to laparotomy required. Major postoperative complications requiring surgical intervention were observed in two cases (9%). One patient (1/22) was diagnosed to have a bowel anastomotic subclinical leak on postoperative day 4 which was managed by

Table 1.
Demographic Characteristics and Symptomatology in Patients of Bowel Deep Infiltrating Endometriosis

	Fertility Conserving Surgery Group (n = 12)	Non-Fertility Conserving Surgery Group (n = 7)	Post Hysterectomy Surgery Group (n = 3)	Total (n = 22)
Demographic				
Age (in years) Mean (min-max)	29.41 (24 – 35)	40.28 (33 – 45)	40.66 (38 – 42)	34.4 (24 – 45)
Body mass index (kg/m ²) Mean (min-max)	23.8 (20.0 – 24.5)	25.4 (23.5 – 26.2)	24.3 (19.4 – 29.3)	24.5 (19.4 – 29.3)
Symptoms:				
Nonspecific				
Chronic pelvic pain	9	4	3	16
Progressive dysmenorrhea	10	7	—	17
Menorrhagia	7	3	—	10
Dyspareunia	9	4	2	15
Bowel specific				
Chronic constipation	4	2	1	7
Dyschezia	12	7	3	22
Hematochezia	—	—	2	2
Catamenial symptoms (fever & vomiting)	1	1	—	2
Bladder specific				
Dysuria	2	1	—	3
Hematuria	—	—	—	0
IIN nerve entrapment	9 (U/L-3, B/L-6)	3 (U/L-1, B/L-2)	2 (B/L-2)	14
Vaginal dryness	7	1	2	10
Perineal pain	9	3	2	14
Gluteal pain	9	3	2	14
Urinary dysfunction (acute retention)	—	1	—	1

Abbreviations: IIN, inferior hypogastric nerve; U/L, unilateral; B/L, bilateral.

emergency diversion ileostomy and the bowel anastomotic rent site was repaired laparoscopically. Final histopathology confirmed it to be a case accompanied by a positive margin with multicentric DIE with multiple occult lesions and associated ulcerative colitis features found at a rectosigmoid junction, sigmoid region, and donut tissue specimen (**Figure 10**). The postoperative patient was comfortable and her diversion ileostomy closure was done after six months. Another case was identified with small bowel obstruction on postoperative day 20. The patient was managed with emergency laparoscopic exploration that revealed intraoperatively an omental band causing stricture on the small bowel which was released, thus relieving the blockage.

Only four cases necessitate readmission in postoperative duration (after 15 days post-surgery) with complaints of

increased frequency of stool following surgery. But all these cases responded to conservative management. None of the patients developed postoperative fever, rectovaginal fistula, pelvic abscess, pelvic hematoma, rectal bleeding, ureterovaginal fistula, or anastomotic site stricture during the postoperative period (**Table 4**).

Seven patients (7/22) completed a follow-up for 12 months, eleven patients (11/22) followed up for 24 months, and four patients (4/22) had 36 – 42-month follow-ups. None of the patients were lost to follow-up during the study duration. VAS scores related to chronic pelvic pain, dysmenorrhea, dyspareunia, dyschezia, gluteal pain, and perineal pain show significant improvement three months after surgery (**Table 5**). None of these patients had any complaints of severe constipation, urinary dysfunction, or fecal incontinence on long-

Table 2
Surgical Procedures Performed in the Study

	Fertility Conserving Surgery Group (n = 12)	Non-Fertility Conserving Surgery Group (n = 7)	Post Hysterectomy Surgery Group (n = 3)	Total (n = 22)
Operative procedures				
Laparoscopic adhesiolysis	12	7	3	22
IHN release	9 (U/L-3, B/L-6)	3 (U/L-1, B/L-2)	2 (B/L)	14
Diseased pelvic peritonectomy	12	7	3	22
Recto-vaginal nodule excision	9	4	2	15
Oophorectomy	1 (U/L)	7 (B/L)	1 (U/L) & 2 (B/L)	2 (U/L) & 9 (B/L)
Cystectomy	10 (U/L-3 & B/L-7)	0	0	10
Ureterolysis	1 (U/L)	3 (U/L)	3 (B/L)	7 (U/L-4 & B/L-3)
D-J stenting	1 (U/L)	3 (U/L)	0	4
Adenomyomectomy	10	—	—	—
Hysterectomy	0	7	—	7
Omental nodule	1	0	0	1
Parametrial nodule	1	3	0	4
Vault nodule	—	—	3	3
Operative parameters				
OT time (mins) Mean (min-max)	167 (135 – 270)	171 (150 – 180)	140 (120 – 150)	165 (120 – 270)
Blood loss (ml) Mean (min-max)	67.5 (50 – 150)	57.14 (50 – 60)	63.33 (30 – 100)	63.33 (30 – 150)

Abbreviations: IHN, inferior hypogastric nerve; U/L, unilateral; B/L, bilateral; D-J, double J stent; OT, operating time.

term follow-up. Only two patients from the fertility-conserving surgery group had recurrence as ovarian endometriomas. These patients had complained of irregular menstrual cycles. Ovarian endometriomas were diagnosed during a follow-up visit with pelvic ultrasound/transvaginal ultrasound after one year of surgery. This was managed conservatively by medical management. Recurrence of symptomatic pelvic DIE was not observed in any of the patients during the follow-up period. A total of four patients (n = 4/12, 33%) conceived post-surgery, one (n = 1/12, 8%) had spontaneous conception one year after surgery, and the rest (n = 3/12, 24%) conceived three years after surgery with the help of assisted reproductive technologies (**Table 6**).

DISCUSSION

The significance of proper assessment of the patient through detailed clinical history and elaborative physical examination cannot be over-emphasized. Comprehensive symptomatology specific to bowel DIE such as dyschezia,

hematochezia, rectorrhagia, or constipation which is cyclical and associated with other symptoms of endometriosis accompanied by exhaustive physical examination is in itself conclusive. IHN nerve involvement may confer some explicit symptoms of gluteal pain, perineal pain, rectal pain, or vaginal dryness. Imaging modalities additionally guide the eventual assertion which further assists in proper pre-operative counseling and formulating a treatment approach. All patients had pre-operative detailed MR colonography which itself has a high positive predictive value for preoperative judgment of the need for bowel DIE segmental resection and anastomosis.¹³

The commonly followed regime for bowel preparation, recommended by various medical societies, is the use of mechanical bowel preparation (MBP) combined with pre-operative oral antibiotics.^{17,18} Few studies have advocated the noninferiority of intravenous preoperative antimicrobial prophylaxis compared to combined pre-operative oral and intravenous antibiotic prophylaxis.¹⁹ The ideal antibiotic regimen has not yet been confirmed. MBP with two doses of intravenous antibiotic prophylaxis was given as

Table 3.
Histopathological Attributes

	Fertility Conserving Surgery Group (n = 12)	Non-Fertility Conserving Surgery Group (n = 7)	Post Hysterectomy Surgery Group (n = 3)	Total (n = 22)
Histopathological examination report				
Length of bowel specimen (in cm) Mean (min-max)	8.6 (6.5 – 13)	9.2 (6 – 13)	9.3 (6.5 – 12)	
Number of endometriotic nodules	-Maximum number of nodules (3) in 2 patients -Multiple nodules (>1) in 6 patients	-Maximum number of nodules (3) in 2 patients -Multiple nodules (>1) in 3 patients	-Maximum number of nodules (2) in 2 patients -Multiple nodules (>1) in 2 patients	
Occult nodule	2	2	0	4
Size of nodule (in cm) Mean (min-max)	-2.7 (1.5 – 4) -Largest 4 cm in 3 patients	-2.5 (1.5 – 6) -Largest 6 cm in 1 patient	-2.1 (1.5 – 3.5) -Largest 3.5 cm in 1 patient	
Margins (in cm) (min-max)	Proximal (2 – 4) Distal (2 – 5)	Proximal (2 – 4) Distal (1.5 – 2.5)	Proximal (2.5 – 5) Distal (1.8 – 2.5)	
Depth of infiltration	Till sub mucosal in all patients	Till sub mucosal in all patients	Till sub mucosal in all patients	
Donut tissue examination	Occult disease present in one case	Occult disease present in one case		
Recto-vaginal nodule size (in cm) Mean (min-max)	4.2 (4.5 – 6)	3.8 (3 – 5.5)	3.2 (3.0 – 3.5)	
Adenomyoma (L × B × H in cm) (mean)	-4.3 × 3.2 × 2 (done in 10 cases) -Largest 7 × 6.5 × 2.5	—	—	10
Ovarian endometrioma	-10 (U/L-3 & B/L-7) -One had fibroma	-6 (U/L-2 & B/L-4) B/L in 4 cases	-3 (U/L-1 & B/L-2)	19
Pelvic peritoneum	All positive for peritoneal endometriosis	All positive for peritoneal endometriosis	All positive for peritoneal endometriosis	22
Uterus-adenomyosis	—	All patients had uterine adenomyosis	—	7
Leiomyomas	—	2 patients had multiple small leiomyomas of varied sizes	—	2
Parametrial nodule	Positive for endometriosis (n = 1)	Positive for endometriosis (n = 3)	Only foci of endometriosis (n = 2)	6
Omental nodule	Positive for endometriosis (n = 1) (4 × 4 cm)	—	—	1
Vault nodule	—	—	Positive for endometriosis (n = 3)	3

U/L, unilateral; B/L, bilateral; LXBXH, length by width by height.

pre-operative bowel preparation in our study. Therefore, more research work is still required to have a conclusive and recommended method of bowel preparation.

Bowel segmental resection techniques for the management of the bowel endometriosis has been performed by laparotomy since the early 1900s. Nezhat et al., as early

as 1992,²⁰ demonstrated the use of techniques for the treatment of deep infiltrating bowel endometriosis. Segmental resection for bowel endometriosis is associated with an increased rate of complications with long-term morbidities, such as bowel and urinary dysfunction. Most surgeons preferred a more conservative surgical approach (shaving or discoid) for the management of bowel DIE, as

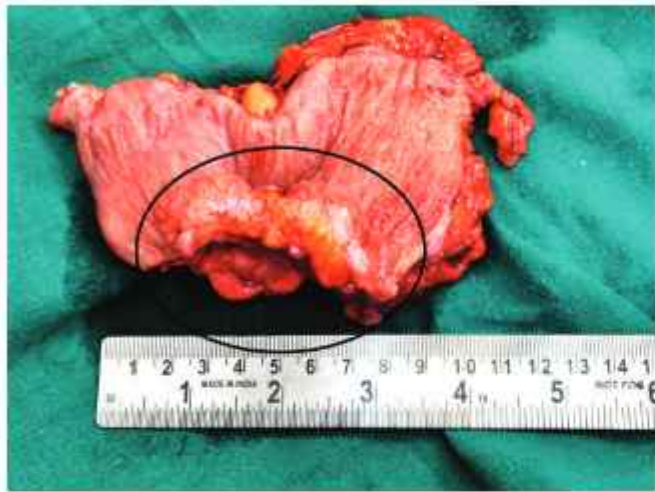

Figure 9. Cut section of rectosigmoid colon specimen with deep infiltrating endometriosis nodule of approximately six centimeters.

these serious long-term morbidities were not accepted for the treatment of benign conditions. Through the years, laparoscopic technological and instrumentation advancement along with enhanced surgeon skill and detailed pelvic anatomical knowledge has led to better surgical management, postoperative, and long-term functional outcomes for patients. Laparoscopic bowel resection techniques for the treatment of bowel DIE has been usually an assisted segmental resection through mini-laparotomy or by port site.⁸ This has led to a further increased risk of wound site infection and thus increased postoperative morbidity.

In contrast, our bowel resection technique has been completely an intracorporeal anastomosis with the benefits of minimally invasive surgery along with a nerve-sparing procedure with acceptable postoperative complications and a better long-term functional outcome. The surgeon in our study employed an intracorporeal hand-sewn purse string suture at the proximal cut end of the colon for anvil fixation. This is more challenging and demands sufficient surgical expertise. Consequently, it is not broadly popular among laparoscopic surgeons chiefly due to restricted proficiency in laparoscopic suturing as well as owing to ergonomic constraints. Nevertheless, this technique of anvil fixation is accomplished over the mini-lap anvil fixation technique owing to minute scar, trivial pain, reduced chances of infection, and shorter hospital stay.¹⁶ The vaginal route for specimen extraction was utilized in all cases in our study which is feasible and secure, as supported by another study as well.²¹

The results demonstrated in our study are proportional to the results of other large studies for symptomatology and histopathological findings.⁸ All patients' body mass index

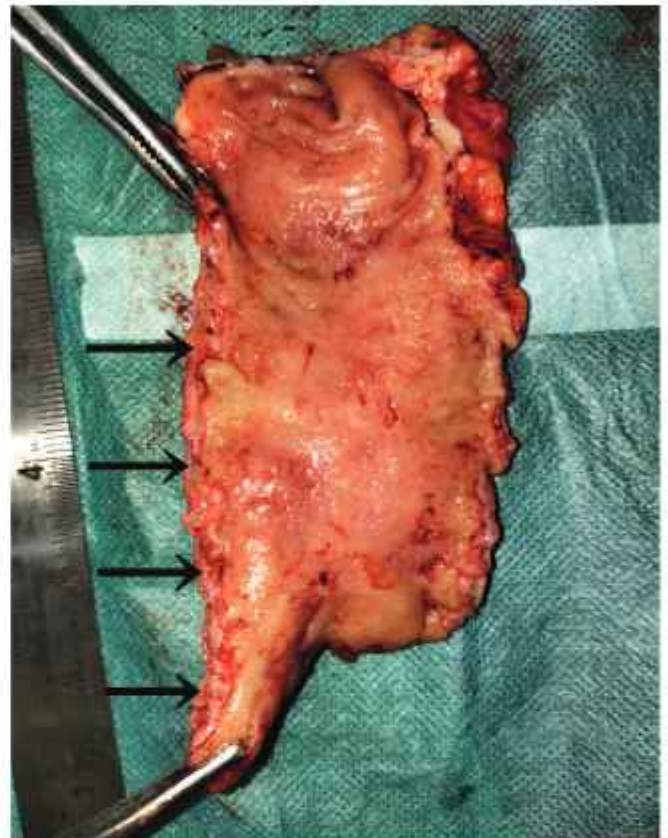


Figure 10. Cut section of rectosigmoid colon specimen with arrow pointing to multiple occult nodules.

scores were within the normal range in our study which is an additional risk factor for the anastomotic leak. Furthermore, operating time and blood loss during surgery, as recorded in our study were also comparable to other studies in the literature and were in the acceptable range. These two are additionally independent risk factors for increased chances of anastomotic leak.⁹ Entrapped IHN symptomatology, clinical features, and its characteristic relief of symptoms following its dissection and release during surgery were perceived in our study and well supported by other studies in the literature.²² Cases with parametrial nodule excision did not complain of any urinary dysfunction post-surgery, as documented in other studies.²³

Pre-operative counseling and postoperative methodology followed in our study, which is also advocated as per ERAS protocol were early mobilizations, injectable anticoagulant, adequate intravenous hydration, limited use of antacid and analgesic, and avoidance of opioid drugs, which further enhance patient recovery. According to ERAS protocol for colon surgery, and gynecology oncology,

Table 4.
Operative Complications

	N = 22
Intraoperative	
Conversion to laparotomy	0
Injury to bladder, bowel, ureter, or major vessel	0
Postoperative (Day 1 - Day 30)	
Postoperative fever (> 38 degrees on 2 or more occasions)	0
Paralytic ileus	0
Anastomotic leak	1 (4.5 %)
Rectovaginal fistula	0
Pelvic abscess	0
Pelvic hematoma	0
Rectal bleeding	0
Uretero-vaginal/ vesicovaginal fistula	0
Bladder dysfunction (urinary retention with prolonged catheterization)	0
Bowel obstruction	1 (4.5 %)
Increased frequency of stool	4 (18.1 %)
Constipation	0
Stricture	0

an intra-abdominal pelvic drain is usually not proposed.¹⁸ This might be approved since it's a planned surgery where bowel segmental resection is typical with a clean and healthy margin. But in cases of bowel DIE managed with segmental resection, there is a possibility of associated multiple occult satellite lesions, near or at the anastomotic line which might hamper the vascularity and further healing at the anastomotic line. Some studies support the fact that these fibrotic satellite occult lesions may be responsible for

Table 6.
Follow-up Outcomes

	N = 22
Follow-up at 3 months	
Chronic pelvic pain	0
Dysmenorrhea	0
Dyspareunia	0
Dyschezia	0
Gluteal & perineal pain	0
Vaginal dryness	0
Long term follow-up (12 – 42 months)	
Bowel functional outcome	
Constipation	0
Fecal incontinence	0
Fecal urgency	0
Recurrence	
Pelvic pain	0
Ovarian endometrioma	2 (9%)
Surgical reintervention	0
Pregnancy outcome (N = 12)	
Spontaneous conception	1 (8.3%)
Assisted Reproductive Technology	3 (25%)

the decrease in postoperative vascularity and thus healing of anastomotic line. This may aggravate the chances of recurrence.²⁴ But further larger studies are required to validate any confirmatory hypothesis. Any new diagnostic modality which might help in the preoperative localization of occult satellite lesions along with an assessment of the vascularity of the respective segment will be a boon to the operating surgeon for preoperative preparation. Thus the placement of the intraperitoneal drain is justified and commended in

Table 5.
Pre- and Post-Surgery Pain Assessment

	No. of Patients (n)	Presurgery (Median)	Post-surgery (Median)	P Value
Visual Analog Score (0–10)				
Chronic pelvic pain	16	6	1	< 0.0001
Dysmenorrhea	10	9	2	0.0020
Dyspareunia	15	9	3	0.0001
Dyschezia	22	8	2	< 0.0001
Gluteal & perineal pain	14	8	1	< 0.0001

our study, against the ERAS protocol. Further guidelines specific to bowel DIE management are warranted, based on the wide available medical literature on the same.

Complications were observed only in two cases, one with a bowel anastomotic leak and the other with an omental band causing bowel obstruction, which is comparatively more acceptable than other studies.^{25,26} The possibility of anastomotic leakage after bowel DIE resection and anastomosis ranges from 1 – 2% to 1 – 6%²⁷ as manifested in various studies. It may be significantly high (20%) depending on the level of anastomosis and length of follow-up. The present study had only one patient (n = 1/22, 4.5%) with an anastomotic leak, who also additionally had IBD (ulcerative colitis) on the final histopathology report. A pertinent surgical methodology was executed in our study to maintain a well-vascularized and tension-free anastomosis to lessen the risk of an anastomotic leak. Preventive maneuvers such as the use of stapled anastomosis, systematic use of pelvic drainage, vaginal closure before the bowel resection procedures, and intra-operative bowel air leak test to check for the integrity of anastomosis were performed. These regimes correlated well with other studies as well.⁹ Ultralow resection was not required in any of the patients as no lesion was present in the low rectum in the present study. Other complications as mentioned in other studies such as recto-vaginal fistula, pelvic abscess, postoperative fever, rectal bleeding, or urinary dysfunction were not elucidated in any of the patients in the present study.⁸

The average duration of follow-up in the study was 12 – 42 months. None of the patients were lost to follow-up during the study duration. Patients did not have any significant long-term bowel-related symptoms after segmental resection of bowel DIE such as severe constipation, fecal incontinence, or urgency.²⁸ All patients had significant improvement in VAS score of symptom-related pain postsurgery during follow-up visits. However large sample size studies are required to validate these findings.

Literature suggests better pregnancy outcomes after conservative bowel surgical technique (shaving) compared to segmental bowel resection for bowel DIE. Our study also demonstrates 33% (4/12) positive pregnancy outcomes. One patient had spontaneous conception after one year of follow up and the other three had to take the help of assisted reproductive technologies. Almost all patients in the fertility preserving group had severe pain components in symptomatology as inked by preoperative VAS score. These patients had deprioritized their desirable fertility due to the pain component. So, patients should be fully counseled regarding the pros and cons of each bowel

operative technique and then allowed to take an informed decision regarding the type of operative procedure. Our small sample size limits us to hypothesize a generalization, but still pregnancy outcome in our study is comparable to other studies.²⁹

Our study had a proper patient selection assisted by pre-operative MRI colonography, which highlights the details of bowel endometriosis as the number and depth of lesions along with any bowel stricture or stenosis. This helps in preoperative patient counseling and thus helps the surgeon to decide on the required bowel surgical technique to be performed. The flaw in our study would be its modest sample size along with its retrospective nature of the study. A 2019 study proclaimed that bowel stenosis was often recurrent in patients who underwent segmental resection of the bowel with circular colorectal anastomosis.³⁰ Therefore follow-up is required to correctly document the data regarding bowel stenosis.

CONCLUSION

Bowel DIE management is an intricate process; nevertheless, it can be executed proficiently by appropriate case selection, detailed clinical history, elaborative physical examination, and corroborative imaging modalities. Apt surgical expertise with exhaustive pelvic anatomy knowledge especially concerning autonomic nerve plexus is further warranted.

References:

1. Nisolle M, Donnez J. Peritoneal endometriosis, ovarian endometriosis, and adenomyotic nodules of the rectovaginal septum are three different entities. *Fertil Steril*. 1997;68(4):585–596.
2. Abo C, Moatassim S, Marty N, et al. Postoperative complications after bowel endometriosis surgery by shaving, disc excision, or segmental resection: a three-arm comparative analysis of 364 consecutive cases. *Fertil Steril*. 2018;109(1):172–178.e1.
3. Veeraswamy A, Lewis M, Mann A, Kotikela S, Hajhosseini B, Nezhat C. Extragenital endometriosis. *Clin Obstet Gynecol*. 2010;53(2):449–466.
4. Keckstein J, Becker CM, Canis M, et al. Recommendations for the surgical treatment of endometriosis. Part 2: deep endometriosis. *Hum Reprod Open*. 2020;(1):hoaa002.
5. Nezhat C, Li A, Falik R, et al. Bowel endometriosis: diagnosis and management. *Am J Obstet Gynecol*. 2018;218(6):549–562.
6. Donnez O, Roman H. Choosing the right surgical technique for deep endometriosis: shaving, disc excision, or bowel resection? *Fertil Steril*. 2017;108(6):931–942.

7. Roman H, Bubenheim M, Huet E, et al. Conservative surgery versus colorectal resection in deep endometriosis infiltrating the rectum: a randomized trial. *Hum Reprod*. 2018;33(1):47–57.
8. Malzoni M, Di Giovanni A, Exacoustos C, et al. Feasibility and safety of laparoscopic-assisted bowel segmental resection for deep infiltrating endometriosis: a retrospective cohort study with description of technique. *J Minim Invasive Gynecol*. 2016;23(4):512–525.
9. Vigueras Smith A, Sumak R, Cabrera R, Kondo W, Ferreira H. Bowel anastomosis leakage following endometriosis surgery: an evidence-based analysis of risk factors and prevention techniques. *Facts Views Vis Obgyn*. 2020;12(3):207–225.
10. Habib N, Gentini G, Lazzeri L, et al. Bowel endometriosis: current perspectives on diagnosis and treatment. *Int J Womens Health*. 2020;12:35–47.
11. Possover M, Andersson KE, Forman A. Neuropelvicology: an emerging discipline for the management of chronic pelvic pain. *Int Neurourol J*. 2017;21(4):243–246.
12. Noventa M, Scioscia M, Schincariol M, et al. Imaging modalities for diagnosis of deep pelvic endometriosis: comparison between trans-vaginal sonography, rectal endoscopy sonography and magnetic resonance imaging. A head-to-head meta-analysis. *Diagnostics (Basel)*. 2019;9(4):225.
13. Scardapane A, Lorusso F, Francavilla M, et al. Magnetic resonance colonography may predict the need for bowel resection in colorectal endometriosis. *Biomed Res Int*. 2017;5981217. Epub 2017 Sep 25.
14. Limbachiya D, Tiwari R, Kumari R. Vault endometriosis: detailed step-by-step laparoscopic surgical management technique. *JSLs*. 2021;25(4):e2021.00057.
15. Limbachiya D, Kumari R. Step-wise technical description of performing ureteric tunnel dissection in laparoscopic radical hysterectomy. *Gynecol Minim Invasive Ther*. 2021;10(4):215–220.
16. Corman ML, Bergamaschi RCM, Nicholls RJ, Fazio VW. *Corman's Colon and Rectal Surgery*. 6th ed. Philadelphia (PA): Lippincott Williams and Wilkins; 2013.
17. Ju YU, Min BW. A review of bowel preparation before colorectal surgery. *Ann Coloproctol*. 2021;37(2):75–84.
18. Nelson G, Bakkum-Gomez J, Kalogera E, et al. Guidelines for perioperative care in gynecologic/oncology: enhanced recovery after surgery (ERAS) society recommendations-2019 update. *Int J Gynecol Cancer*. 2019;29(4):651–668.
19. Ikeda A, Konishi T, Ueno M, et al. Randomized clinical trial of oral and intravenous versus intravenous antibiotic prophylaxis for laparoscopic colorectal resection. *Br J Surg*. 2016;103(12):1608–1615.
20. Nezhat C, Nezhat F, Pennington E. Laparoscopic treatment of infiltrative rectosigmoid colon and rectovaginal septum endometriosis by the technique of videolaparoscopy and the CO2 laser. *Br J Obstet Gynaecol*. 1992;99(8):664–667.
21. Spagnolo E, Mari-Alexandre J, Di Saverio S, et al. Feasibility and safety of transvaginal specimen extraction in deep endometriosis colorectal resectional surgery and analysis of risk factors for postoperative complications. *Tech Coloproctol*. 2022;26(4):261–270.
22. Ceccaroni M, Clarizia R, Bruni F, et al. Nerve-sparing laparoscopic eradication of deep endometriosis with segmental rectal and parametrial resection: the Negrar method. A single-center, prospective, clinical trial. *Surg Endosc*. 2012;26(7):2029–2045.
23. Benoit L, Dabi Y, Bazot M, et al. Parametrial endometriosis: a predictive and prognostic factor for voiding dysfunction and complications. *Eur J Obstet Gynecol Reprod Biol*. 2022;276:236–243.
24. Roman H, Merlot B, Forestier D, et al. Nonvisualized palpable bowel endometriotic satellites. *Hum Reprod*. 2021;36(3):656–665.
25. Bendifallah S, Puchar A, Vesale E, Moawad G, Daraï E, Roman H. Surgical outcomes after colorectal surgery for endometriosis: a systematic review and meta-analysis. *J Minim Invasive Gynecol*. 2021;28(3):453–466.
26. Casas SGL, Spagnolo E, Saverio SD, et al. Short-term outcomes in patients undergoing laparoscopic surgery for deep infiltrative endometriosis with rectal involvement: a single-center experience of 168 cases. *Ann Coloproctol*. 2022, Mar 7. Epub ahead of print.
27. De Cicco C, Corona R, Schonman R, Mailova K, Ussia A, Koninckx P. Bowel resection for deep endometriosis: a systematic review. *BJOG*. 2011;118(3):285–291.
28. Soto E, Catenacci M, Bedient C, Jelovsek JE, Falcone T. Assessment of long-term bowel symptoms after segmental resection of deeply infiltrating endometriosis: a matched cohort study. *J Minim Invasive Gynecol*. 2016;23(5):753–759.
29. Mohr C, Nezhat FR, Nezhat CH, et al. Fertility considerations in laparoscopic treatment of infiltrative bowel endometriosis. *JSLs*. 2005;9(1):16–24.
30. Bertocchi E, Barugola G, Benini M, et al. Colorectal anastomotic stenosis: lessons learned after 1643 colorectal resections for deep infiltrating endometriosis. *J Minim Invasive Gynecol*. 2019;26(1):100–104.